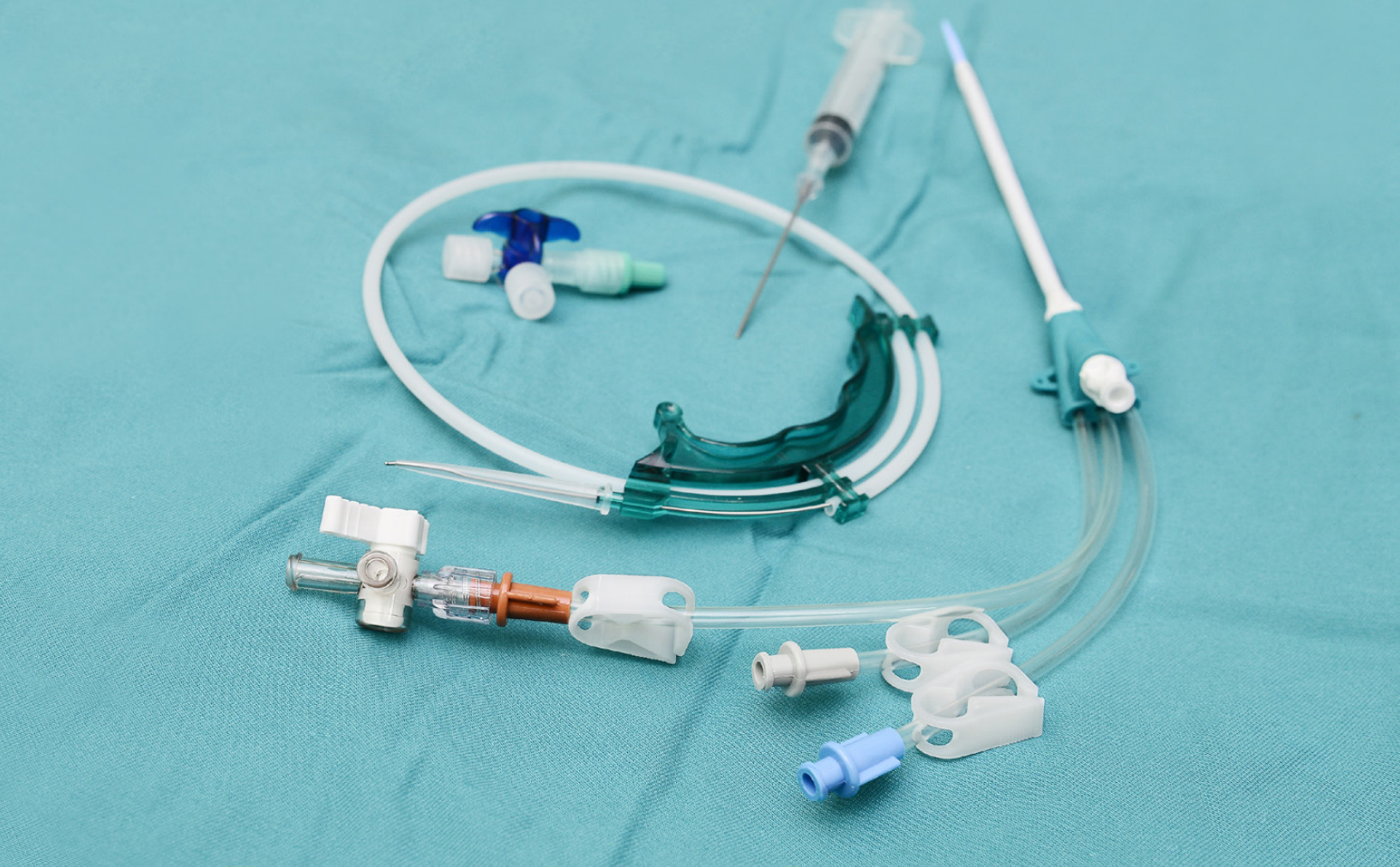



PROVINCIAL STANDARDS & GUIDELINES



Insertion and Removal of Tunneled Hemodialysis Catheters

Reviewed May 2017

Developed by the BCPRA Hemodialysis Committee

Table of Contents

1.0 Scope 1

2.0 Recommendations 1

3.0 Rationale 2

4.0 Prescriber’s Orders For Alteplase Use For Occluded HD Catheters 3

5.0 Sponsors 5

6.0 Effective Date 5



IMPORTANT INFORMATION




This BCPRA guideline/resource was developed to support equitable, best practice care for patients with chronic kidney disease living in BC. The guideline/resource promotes standardized practices and is intended to assist renal programs in providing care that is reflected in quality patient outcome measurements. Based on the best information available at the time of publication, this guideline/resource relies on evidence and avoids opinion-based statements where possible; refer to www.bcrenalagency.ca for the most recent version.

For information about the use and referencing of BCPRA provincial guidelines/resources, refer to <http://bit.ly/28SFr4n>.



BC Provincial Renal Agency
(BCPRA)
700-1380 Burrard Street
Vancouver, BC V6Z 2H3

Phone: 604-875-7340
Email: bcpra@bcpra.ca
Web: BCRenalAgency.ca

 Facebook.com/BCRenalAgency
 [@BCRenalAgency](https://twitter.com/BCRenalAgency)
 Youtube.com/BCRenalAgency

Insertion and Removal of Tunneled Hemodialysis Catheters

1.0 Scope of Guideline

An arteriovenous (AV) fistula is the recommended access for chronic hemodialysis adult patients. Despite this recommendation, tunneled cuffed hemodialysis catheters are required to be used in select groups of patients (see recommendation #1). This guideline outlines the indications for the use of tunneled cuffed hemodialysis catheters, method of insertion, and methods of removal.

For paediatrics, current K/DOQI recommendations - although not evidence based - support catheters being the FIRST access in children if a transplant is expected within 1 year. Catheters are also most likely to be the access of choice in children weighing ≤ 20 kg or in situations where the child's developmental level precludes safe cannulation.

Related Guidelines:

- BC Provincial Renal Agency. *Provincial Recommendations for VA for Patients with HD as their Primary Modality*, 2013.
- Canadian Society of Nephrology Guidelines. Chapter 4: Vascular Access, *Journal of American Society of Nephrology*, 17: S16-S23, 2006.
- National Kidney Foundation. KDOQI Clinical Practice Guidelines and Clinical Practice Recommendations for 2006 Updates: Hemodialysis Adequacy, Peritoneal Dialysis Adequacy and Vascular Access. Guideline 2: Selection and Placement of HD Access,

American Journal of Kidney Disease, 48:S192-S200, 2006 (suppl 1).

2.0 Recommendations

Recommendation 1:

A tunneled, cuffed hemodialysis catheter is the access of choice for temporary hemodialysis of greater than two to three weeks duration (evidence).

Other indications for the use of tunneled, cuffed hemodialysis catheters include:

- permanent hemodialysis (HD) access when no other access options exist
- when a fistula or graft is maturing
- when a peritoneal dialysis (PD) tube is planned or healing
- when a live donor transplant is scheduled
- children weighing ≤ 20 kg or in situations where the child's developmental level precludes safe cannulation.

Recommendation 2:

The preferred site for tunneled cuffed hemodialysis catheters is the right internal jugular vein (evidence).

Other options than the right internal jugular vein include:

- left internal jugular vein,
- right or left external jugular vein
- subclavian veins - only when jugular options are not available
- femoral veins
- translumbar or transhepatic access to the inferior vena cava

Insertion and Removal of Tunneled Hemodialysis Catheters

Notes re site selection:

- Tunneled cuffed catheters should not be placed on the same side as a maturing or planned AV access, if possible.
- If a femoral vein is chosen, the length of the catheter must be at least 20 cm to avoid recirculation.

Recommendation 3:

Tunneled, cuffed hemodialysis catheters are inserted by, or under the supervision of, trained personnel under fluoroscopy. Exception: Femoral catheters are inserted under ultrasound. (evidence).

Notes re insertion:

- Surgical placement in the operating room is also acceptable.
- Complication rates should be <0.1% for pneumothorax, <1% for carotid puncture and <10% for early catheter malfunction.
- If a catheter is not placed under fluoroscopy, then ultrasound guidance is recommended for insertion (evidence).
- If a catheter is not placed under fluoroscopy, a chest x-ray is strongly advised (and supported by evidence) prior to line use to ensure proper position and exclude complications (excludes femoral catheters).

Recommendation 4:

Using fluoroscopy, the catheter tip is adjusted so the tip is in the mid right atrium when the patient is supine (proximal right atrium when the patient is sitting) (evidence).

Recommendation 5:

Prophylactic antibiotic coverage is not recommended prior to line insertion (no evidence to support the use of prophylactic antibiotics).

Recommendation 6:

Removal of tunneled cuffed hemodialysis catheters may be performed using venous cutdown or traction, depending upon how the catheter was inserted (evidence).

3.0 Rationale

Once inserted, a tunneled cuffed catheter requires no maturation and can be used immediately for hemodialysis.¹ This convenience, however, comes with many disadvantages including high patient morbidity due to infection, thrombosis and the risk of central vein stenosis. They also achieve lower blood flow rates than other access types.

The right internal jugular vein offers the most direct route to the caval atrial junction, leading to greater blood flow rates and less stenosis and thrombosis when compared to left sided vessels. However, if an arteriovenous (AV) fistula or graft is planned, the cuffed catheter should be placed in the contralateral internal jugular vein.

The optimal tip position is poorly studied. The K/DOQI guidelines recommend positioning the tip within the right atrium. The tip is placed distally in the right atrium while the patient is lying in a supine position during insertion, as it will retract

Insertion and Removal of Tunneled Hemodialysis Catheters

proximally by several centimeters when the patient returns to an upright position. However, the mid right atrium is ideally suited for the catheter tip due to its large caliber space, reducing inadvertent mural wall trauma (Mokrzycki and Lok, 2010).

Subclavian vein catheters are discouraged as they have been found to have higher complication rates and a higher incidence of central vein stenosis and thrombosis when compared with internal jugular vein catheters²⁻⁶.

Ultrasound guided insertion has been shown to limit insertion related complications in several studies⁷⁻¹⁰, including a 68% reduction in failure rate, 78% reduction in complication rate and 40% reduction in number of attempts in one meta-analysis.⁷

Fluoroscopy allows ideal catheter tip placement to maximize blood flow. In several studies¹¹⁻¹⁴, interventional radiologic placement of tunneled hemodialysis catheters showed equal or better long-term results than those reported for surgical placement.

Employing imaging-guided placement with both ultrasound guidance for venous puncture and fluoroscopy for catheter placement and positioning has been shown to reduce the rate of initial malfunction from as high as 14%¹ to near zero^{12, 13}. The rate of major complications has also shown to decrease from a high of 5.9% to near zero.¹⁴

Evidence is lacking to support the prophylactic use of antibiotics at the time of catheter placement. Several randomized controlled trials of patients with cancer have shown no benefit to this strategy.^{15, 16} A Cochrane systematic review also failed to show a reduction in catheter related infections with prophylactic antibiotics.¹⁷

Catheter removal can be performed with traction or cutdown. Cuff retention occurs in approximately 10% of catheters removed with traction and these retained cuffs are generally of no consequence, rarely requiring removal with cutdown for cuff migration to the exit site, infection or poor healing.¹⁸

4.0 References

Beathard GA, Litchfield T. Effectiveness and safety of dialysis vascular access procedures performed by interventional nephrologists. *Kidney Int* 2004 Oct; 66(4):1622-32.

Caridi J, Grundy L, Ross E, et al. Interventional radiology placement of twin Tesio catheters for dialysis access; review of 75 patients. *J Vasc Inter Radiol* 1999; 10:78-83.

Cimochowski GE, Worley E, Rutherford WE, Sartain J, Blondin J, Harter H. Superiority of the internal jugular over the subclavian access for temporary dialysis. *Nephron* 1990; 54:154-16.

Denys BG, Uretsky BF, Sudhakar R, Ultrasound-assisted cannulation of

Insertion and Removal of Tunneled Hemodialysis Catheters

the internal jugular vein: A prospective comparison to the external landmark-guided technique for acute haemodialysis access. *Nephrol Dial Transplant* 1997; 12: 1234-1237.

Headley CM, Thompson CL, Carter M, Khan A, Wall BM. The role of real-time ultrasound and physical examination measurements in placement of cuffed-tunneled hemodialysis catheters. *Nephrol Nurs J*. 2004 Jul-Aug; 31(4):407-10; 416-19.

Kohli MD, Trerotola SO, Namyslowski J, Stecker MS, McLennan G, Patel NH, Johnson MS, Shah H, Seshadri R. Outcome of Polyester Cuff Retention Following Traction Removal of Tunneled Central Venous Catheters. *Radiology* 2001; 219:651-654.

Lin BS, Kong CW, Tarng DC, Huang TP, Tang GJ. Anatomical variation of the internal jugular vein and its impact on temporary haemodialysis vascular access; an ultrasonographic survey in uraemic patients. *Nephrol Dial Transplant* 1998; 13: 134-138.

Lund GB, Trerotola SO, Scheel PF, Savader SJ, Mitchell SE, Venbrux AC, Osterman FA: Outcome of tunneled hemodialysis catheters placed by radiologists. *Radiology* 1996: 467-472, 1996.

McKee R, Dunsmuir R, Whitby M, Garden OJ. Does antibiotic prophylaxis at the time of catheter insertion reduce the incidence

of catheter-related sepsis in intravenous nutrition? *J Hosp Infect* 1985; 6:419-425. Mokrzycki, Michele and Lok, Charmaine. (2010). Traditional and non-traditional strategies to optimize catheter function: go with more flow. *Kidney International*: 78, 1218-1231.

Moss AH, Vasilakis C, Holley JL, Foulks CJ, Pillai K, McDowell DE: Use of a silicone dual-lumen catheter with a Dacron cuff as a long-term vascular access for hemodialysis patients. *Am J Kidney Dis* 16:211-215, 1990.

Randolph AG, Cook DJ, Gonzales CA, Pribble CG. Ultrasound guidance for placement of central venous catheters: A meta-analysis of the literature. *Crit Care Med* 1996; 24: 2053-2058.

Ranson MR, Oppenheim BA, Jackson A, Kamthan AG, Scarffe JH. Double-blind placebo controlled study of vancomycin prophylaxis for central venous catheter insertion in cancer patients. *J Hosp Infect* 1990; 15:95-102.

Schwab SJ, Quarles LD, Middleton JP, Cohan RH, Saeed M, Dennis VW. Hemodialysis-associated subclavian vein stenosis. *Kidney Int* 1988; 33:1156-1159.

Schillinger F, Schillinger D, Montagnac R, Milcent T. Post catheterization vein stenosis in haemodialysis: comparative angiographic study of 50 subclavian and 50 internal jugular accesses. *Nephrol Dial Transplant* 1991; 6:722-724.

Insertion and Removal of Tunneled Hemodialysis Catheters

Skolnick ML: The role of sonography in the placement and management of jugular and subclavian central venous catheters. *Am J Roentgenol* 163:291-295, 1994.

Trerotola SO, Kuhn-Fulton J, Johnson MS, Shah H, Ambrosius WT, Kneebone PH. Tunneled infusion catheters: increased incidence of symptomatic venous thrombosis after subclavian versus internal jugular venous access. *Radiology* 2000; 217:89-93.

Trerotola SO, Johnson MS, Harris VJ, Shah H, Ambrosius WT, McKusky MA, Kraus MA. Outcome of Tunneled Hemodialysis Catheters placed via the right internal jugular vein by interventional radiologists. *Radiology* 1997; 203: 489-495.

Van de Wetering MD, van Woensel JB, Kremer LC, Caron HN. Prophylactic antibiotics for preventing early Gram-positive central venous catheter infections in oncology patients, a Cochrane systematic review. *Cancer Treat Rev* 2005; May 31(3):186-96.

5.0 Sponsors

This provincial guideline was developed to support improvements in the quality of vascular access care delivered to patients with chronic kidney disease in BC. Based on the best information available at the time it was published, the guideline relies on evidence and avoids opinion-based statements where possible. When used in conjunction with pertinent clinical data, it is a tool that health authorities and health professionals can use to develop local guidelines.

1. Developed by the BC Vascular Access Educators Group, the guideline was approved by the BC Provincial Renal Agency (BCPRA) HD Committee and the BCPRA Medical Advisory Committee (approved 2011 version; only minor changes in 2015 version). It has been adopted by BCPRA as a provincial guideline.

6.0 Effective Date

- Effective date: 2007; Revision dates: Sept 9, 2011; Sept 2, 2015.
- This guideline is based on scientific evidence available at the time of the effective date; refer to www.bcrenalagency.ca for most recent version.